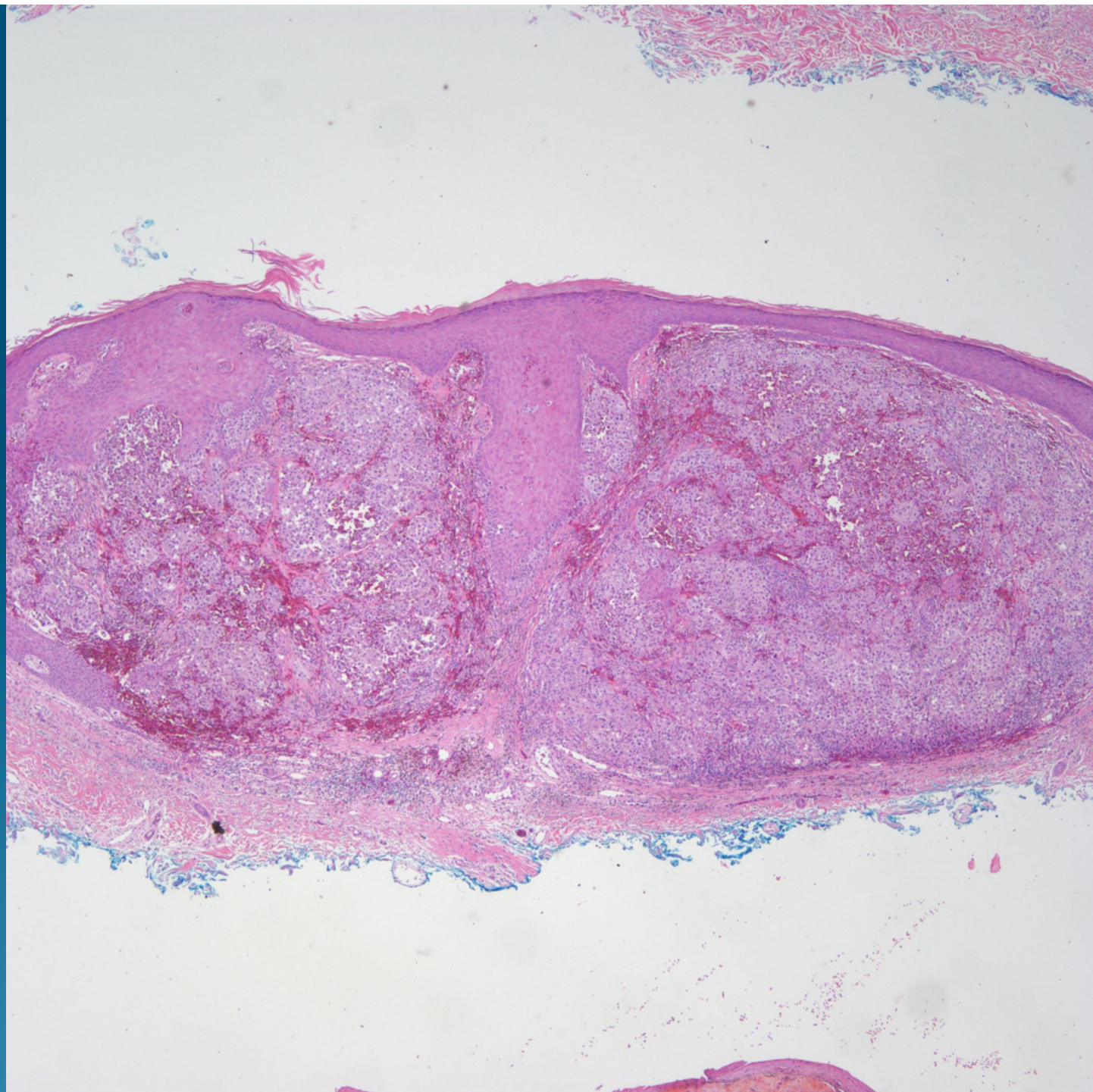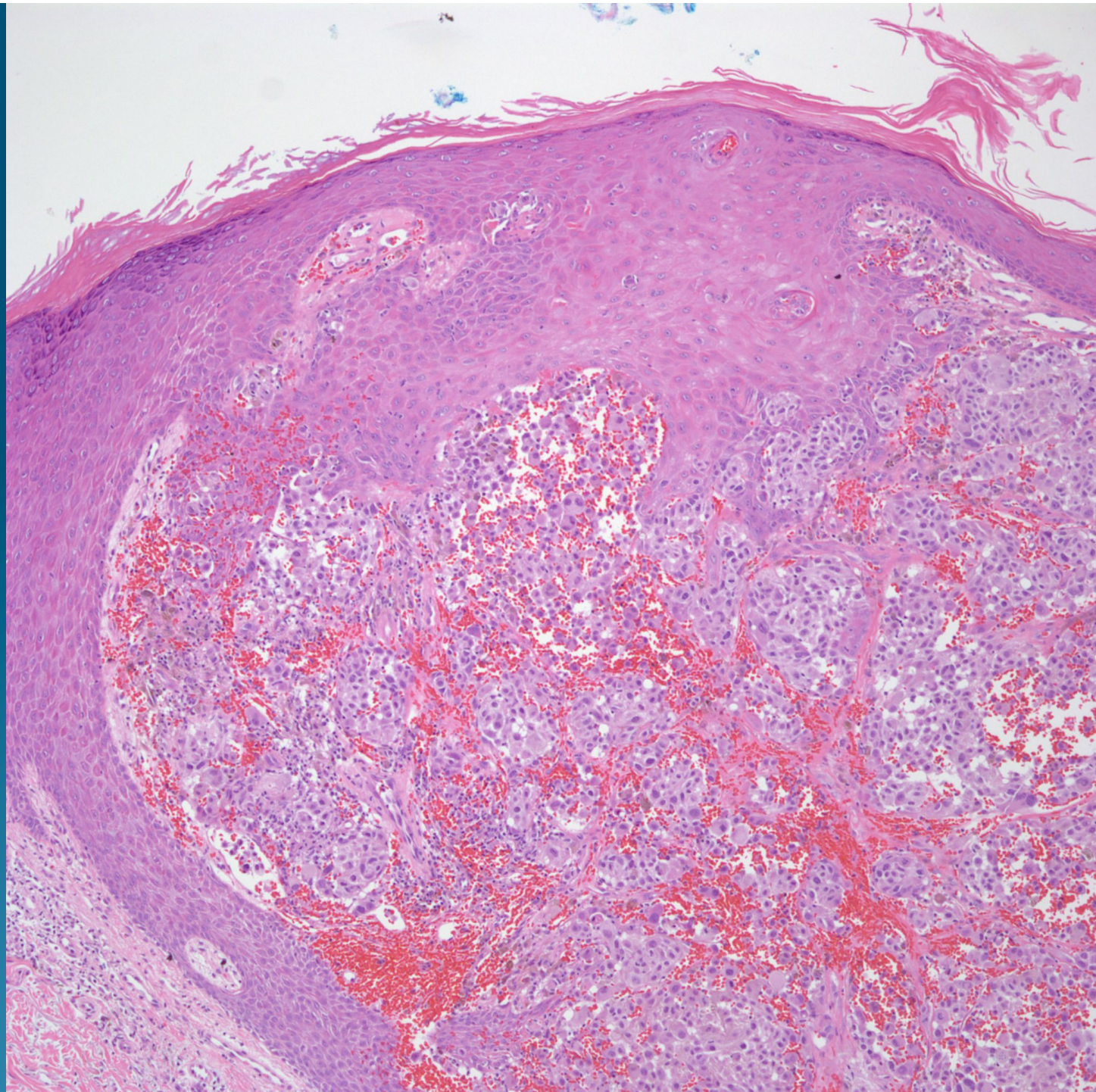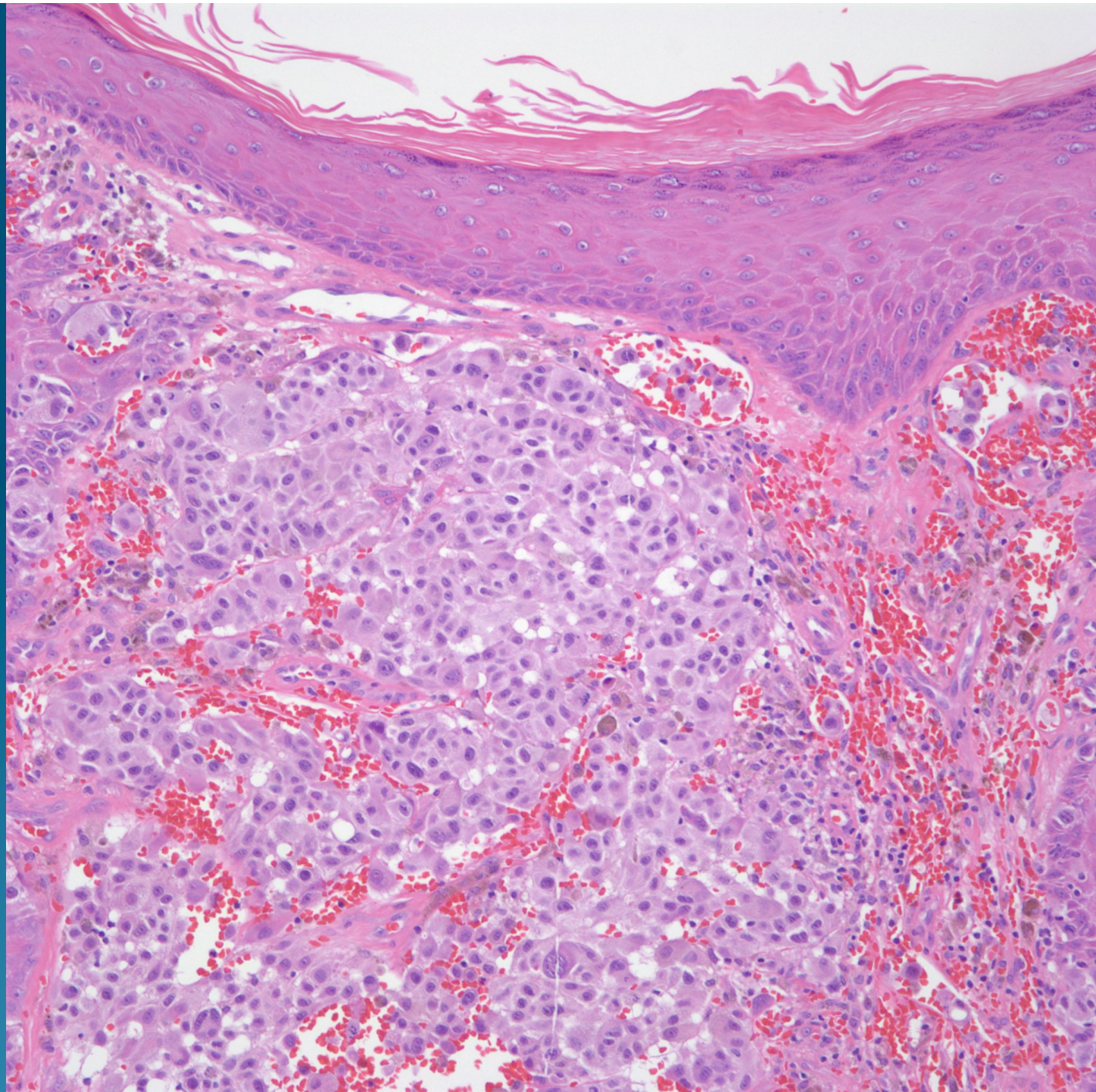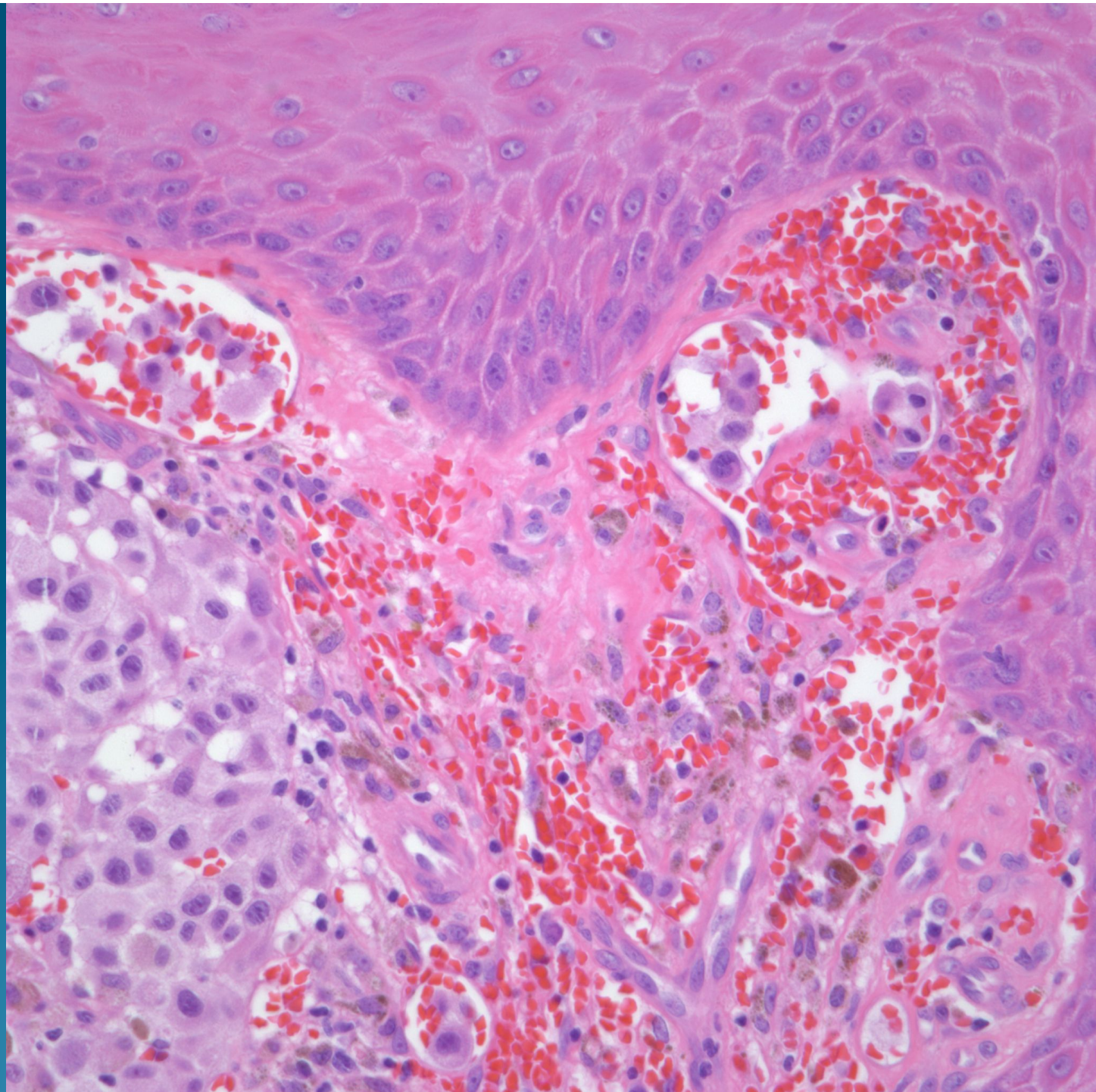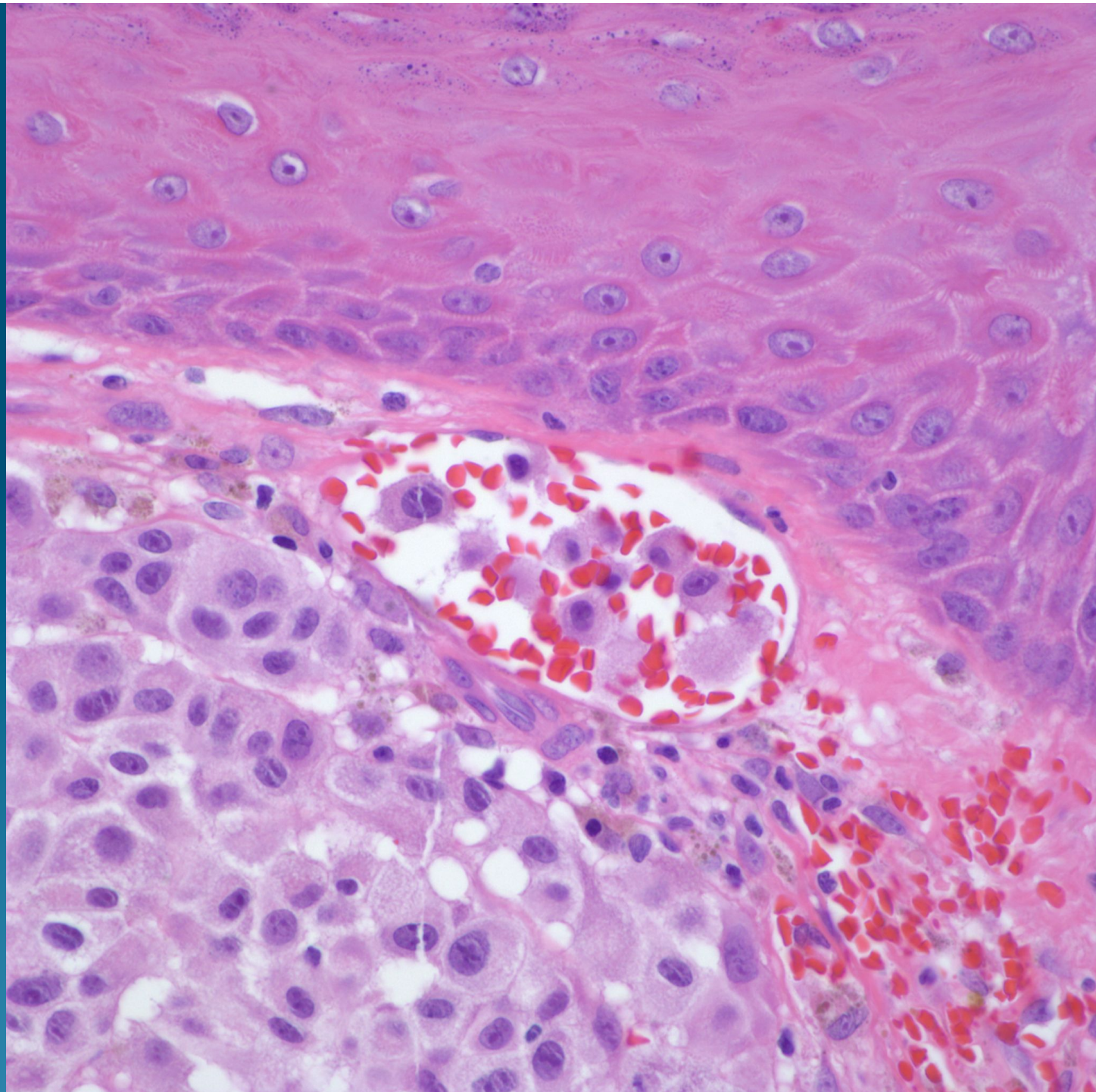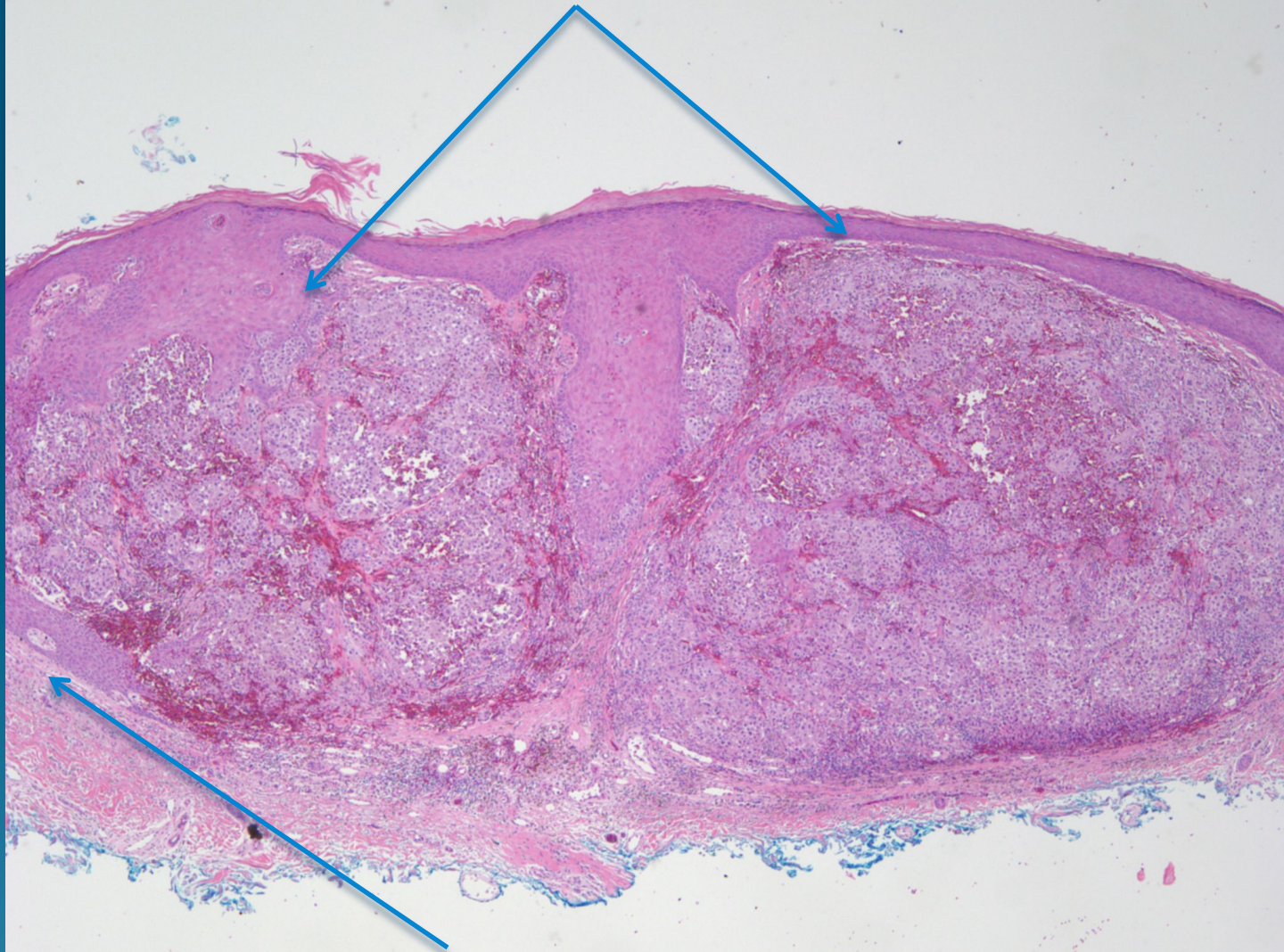


# Nodular Malignant Melanoma with Lymphovascular Invasion



Expansile asymmetric nodule of malignant melanocytes



Radial growth phase does not extend beyond  
Three rete ridges from invasive vertical growth